



PATIENT

Ellie Stockley

SPECIES

Canine

BREED

Chihuahua

SEX

Female Spayed

AGE

7 years

WEIGHT

7.4lbs

INTERPRETED BY

Maggie Machen
Lamy, DVM
DACVIM (Cardiology)

IMAGING PERFORMED BY

Pamela Harrigan,
RDMS

HOSPITAL NAME

Norfolk County
Veterinary Service

REFERRING VET

Dr. Leoni

INVOICE

24968

DATE

6/23/22

PRESENTING CLINICAL SIGNS

History: Recheck echo. History chronic valvular disease - Stage B1. History systemic hypertension (on Enalapril 2.5mg, 1/2-tab BID). Currently, doing well at home. BP: 130mmHg. -Pertinent previous echo findings (9/2/21 Maggie Machen Lamy, DVM, DACVIM-Cardiology): LA 1.7 cm; LA:Ao 1.6; LV 2.3 cm; mild LAE; mild-moderate MR; mild TR (3.4 m/s; 46 mmHg); mild pulmonary hypertension.

ECHOCARDIOGRAM FINDINGS

2D, m-mode, color flow and Doppler imaging is available.

Left ventricle: The LV diameter is normal with adequate myocardial function. LV wall thicknesses are normal.

Left atrium: The left atrium is mildly dilated.

Mitral valve: The mitral valve is diffusely thickened with mild prolapse into the left atrial lumen. Mild to moderate eccentric mitral regurgitation with a normal velocity.

Aortic valve/aorta: The aortic valve is normal in morphology and mobility. Normal aortic outflow velocity; laminar flow. No aortic insufficiency.

Right ventricle: Normal right ventricular diameter and morphology.

Right atrium: Normal RA dimension.

Tricuspid valve: The tricuspid valve appears mildly thickened with mild tricuspid regurgitation; velocity consistent with mild PAH.

Pulmonic valve/pulmonary artery: The pulmonic valve is normal in morphology and mobility. No pulmonic insufficiency. Normal RVOT velocity; laminar flow.

Pericardium/other: No pericardial or pleural effusion noted. No obvious cardiac masses.

Heart rhythm: ECG reveals a sinus rhythm with an average HR of 150bpm.

2-Dimensional Measurements

Ao diam (cm)	1.1
LA diam (cm)	1.7
LA:Ao (Swe)	1.6
IVS thickness (cm)	0.6
LVID diastole (cm)	2.2
PW thickness (cm)	0.6
LVID systole (cm)	1.0
FS (%)	56

Doppler Measurements

PV Vmax (m/s)	0.8
AoV Vmax (m/s)	1.5
MR Vmax (m/s)	5.0
TR Vmax (m/s)	3.0
TR PG (mmHg)	36

INTERPRETATION OF THE FINDINGS

Chronic degenerative valve disease persists with relative stability. While the MR is quantitatively increased, the left heart dimensions are unchanged. Mild PAH is similar to previous, with no additional issues identified.

Continued assessment of progression in the future will help predict long term prognosis, which is highly variable at this stage (B1).

RECOMMENDATIONS

- In an asymptomatic dog without significant left atrial enlargement, no cardiac medications are clearly indicated.
- Omega fatty acid supplementation and mild salt restriction may be of some long term benefit.



PATIENT

Ellie Stockley

SPECIES

Canine

BREED

Chihuahua

SEX

Female Spayed

AGE

7 years

WEIGHT

7.4lbs

INTERPRETED BY

Maggie Machen
 Lamy, DVM
 DACVIM (Cardiology)

IMAGING PERFORMED BY

Pamela Harrigan,
 RDCS

HOSPITAL NAME

Norfolk County
 Veterinary Service

REFERRING VET

Dr. Leoni

INVOICE

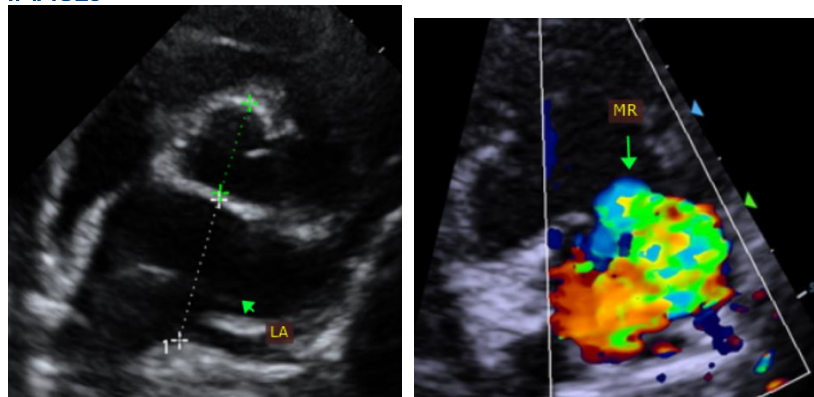
24968

DATE

6/23/22

- Anesthetic risk is considered mild if needed. Cardiac protective drug choices (opioid/benzodiazepine premedication, propofol or alfaxalone induction, isoflurane gas) are recommended. Pre-oxygenate for 5-10 minutes prior to induction. Monitor for arrhythmias, hypotension, and hypoxia both intra and post-operatively and intervene as necessary. Mild IV fluid restriction is recommended to avoid fluid overload. Avoid heart rate stimulating drugs such as atropine unless clinically indicated.
 - Monitor for development of a cough, labored breathing, exercise intolerance or collapse episodes.
- PLAN**
- Recommend conservative monitoring with a recheck echocardiogram in 6 months, sooner if any development of clinical signs.

IMAGES



The information and recommendations provided are based on the images presented by the referring veterinarian. No evaluation can be communicated regarding pathology that was not visible in the image/video clips provided.

Thank you for this referral. This report was generated using transcription software, and minor dictation errors may be present. If the clinical or image interpretation does not parallel your findings or if I can be of any further assistance, please contact me.

Maggie Machen Lamy, DVM
Diplomate of the American College of Veterinary Internal Medicine (Cardiology)
 info@sonopath.com